

**ALUMINUM AND FLUORIDE IMPACTS CORTEX AND HIPPOCAMPUS STRUCTURE IN RATS: PROTECTIVE ROLE OF RESVERATROL**


CSReddy Nallagouni and K. Pratap Reddy\*

Department of Zoology, University college of Science, Osmania University, Hyderabad, India.

**ABSTRACT:** Metals such as aluminum and Fluoride have been implicated in the etiology of several neurodegenerative disorders. Resveratrol, a natural polyphenol, exerting a wide range of biological and pharmacological activities including its antioxidative properties against neurodegenerative disorders through its ability to lessen oxidative stress. Rats were divided into 4 groups. Group –I was served as control. Group –II was intoxicated with AlCl<sub>3</sub> (100 mg/kg b.w) along with Sodium fluoride (10 mg/kg b.w). Group –III was administered with AlCl<sub>3</sub> (100 mg/kg b.w) + Sodium fluoride (10 mg/kg b.w) + resveretrol (30 mg/kg b.w). Group–IV was administered with resveretrol (30 mg/kg b.w) alone for 8 weeks. The obtained results showed significant oxidative stress induced neuronal damage in cerebral cortex and hippocampus in intoxicated rats where as significant reduction in neuronal damage in the rats administered with resveratrol against aluminium along with fluoride. Hence, the results of the present study reveal that the resveratrol has potential neuroprotective properties to reverse the cortical and hippocampal neuronal damage induced by aluminum and fluoride intoxication

**Key words:** Aluminium, Fluoride, Resveratrol, cortex, Hippocampus

\*Corresponding author: K. Pratap Reddy, Department of Zoology, University college of Science, Osmania University, Hyderabad, India

Copyright: ©2017 K. Pratap Reddy. This is an open-access article distributed under the terms of the Creative Commons Attribution License , which permits unrestricted use, distribution, and reproduction in any medium, provided the original author and source are credited

**INTRODUCTION**

Polyphenols have a role as novel “natural drug” agents in the prevention and possible therapy of neurodegenerative disorders. Resveratrol, a polyphenol, exerts potent antioxidant activity because of its ability to up regulate endogenous antioxidant enzymes to scavenge free radicals (Belguendouz et al., 1997; Lastra and Villegas, 2005). Resveratrol protects cells from oxidative stress, excitotoxicity, and dysregulation of autophagy (Jeong et al., 2012; Ko et al., 2015). Resveratrol can scavenge and neutralize hydroxyl, superoxide, and metal-induced free radicals (Rossi et al., 2013; Saw et al., 2014). Besides acting as a reactive oxygen species scavenger, Resveratrol has been reported to activate intracellular signaling necessary to mount anti-oxidative defenses. Resveratrol is able to protect and even rescue hippocampal neurons that were exposed to nitric oxide (NO), an effect that could be explained, at least in part, by its purported antioxidant activities, as well as its reactive oxygen species scavenging properties (Stéphane et al., 2015). Resveratrol (50 or 100 mM) protected HT22 cells, a hippocampal neuronal cell-line, against glutamate-induced oxidative stress and neurotoxicity by activating PI3K/Akt and GSK-3b/b-catenin signaling pathways to induce manganese superoxide-dismutase (MnSOD) expression and thereby reduce mitochondrial dysregulation (Frombaum et al., 2012).

Aluminium is one of the potent neurotoxic metals that can cross the blood brain barrier via iron binding protein, transferrin (Yokel, 2006; Song et al., 2008). The chronic treatment of animals with Aluminium is associated with neuro behavioural, neurochemical, and neuro pathological alterations (Lakshmi et al., 2014; Celeste et al., 2014; Prakash et al., 2013). Aluminium can induce oxidative damage, cholinergic dysfunction and associated cognitive impairments in cerebral cortex of male Wistar rats (Poonam et al, 2015). Aluminium also induces memory impairment and mitochondrial oxidative damage leading to neurotoxicity in rats (Prakash et al., 2013) and histopathological alterations in brain of female rats (Ahmed, 2012). Increased oxidative stress, increased level of cholesterol, chronic inflammation, loss of cholinergic activity, unregulated glutamate signaling, formation of amyloid beta plaques, tau hyperphosphorylation, neurofibrillary tangles are the manifestations associated with AD, one of the major neurodegenerative disorders (Humpel, 2011). Lipid peroxidation, a marker of oxidative stress, is one of the mechanisms which induces neurotoxicity (Goma and Mahrous 2013; Stevanoic et al. 2010). Increased lipid peroxidation has been reported after long term low level aluminium exposure (Kaizer et al. 2005). Oxidative damage, beta-amyloid (Ab) deposits, s-protein aggregation and reduction in the levels of neurotransmitter acetylcholine seems to play significant roles in the disease progression of Alzheimer's disease, one of neurodegenerative disorders (Querfurth and La Ferla, 2010, Ansari and Scheff, 2010). It is very clear that aluminum affects the cortex (Urano et al., 1997) and hippocampus regions (Deloncle and Guillard, 1990) profoundly than any other area of the central nervous system. These brain regions are well-known to be predominantly susceptible in Alzheimer's disease and have an important role in learning and memory functions. For these reasons cortex and dentate gyrus, part of the hippocampal formation was chosen for the study.

In other hand, number of studies have clearly shown that F increases brain ROS and LPO activity. Excessive ingestion of Fluoride (F) can exert toxic effects on many tissues and organs, resulting in serious damage and pathological changes. A number of histopathological changes, including demyelination, decrease in the number of Purkinje cells, thick and disappearance of dendrites, swelling of mitochondria and dilation of endoplasmic reticulum in neurons, have been observed in the brain of experimental animals subjected to fluorosis. Accumulation of F also been observed in the brains of experimental animals exposed to high doses of F for a prolonged period. Alteration in the BBB can also promote inflammation involving activated microglia which may be preferentially associated with the amyloid plaques, these capillary distortions can disrupt blood flow patterns, altering cerebral metabolism and if sustained, contribute to progressive degeneration of neurons.

Fluoride damage to neurons can reflect both an increase in oxidative processes and a decrease in antioxidant defenses. Fluorosis patients may undergo neurodegeneration by fluoride induced oxidative stress (Sharma et al., 2014). Furthermore, the role of fluorine in aluminum neurotoxicity has been addressed by Van der et al (1999) using cultured cells of the hippocampus obtained from rat fetuses and exposed to NaF or AlF<sub>3</sub>, either separately or in combination. When AlF<sub>3</sub> was administered alone, the formation of connections between nerve fibers was abnormal. This effect was increased when AlF<sub>3</sub> was combined with NaF. Apparently, aluminum interferes with the metabolism of the cytoskeleton in the nerve cells and the effect is potentiated by fluorine. The simultaneous administration of both elements produced aggregates of hippocampal neurons. In a study carried out by Varner et al (1998) they observed deposition of Al in the kidneys of rats and postulated role of AlFx complex in the transport and penetration of Al across the blood-brain barrier. A series of investigation have proven that AlFx is a brain toxin as well as neurotoxic (Varner et al., 1998). Hence, the study reports the protective effects of resveratrol against aluminium and fluoride induced structural and degenerative changes in cortex and hippocampus in rat brain.

## **MATERIALS AND METHODS**

### **Chemicals and Animals**

## **MATERIALS AND METHODS**

### **CHEMICALS AND ANIMALS**

Resveratrol, aluminum and fluoride were administered through the diet as trans- resveratrol, Al chloride and Na fluoride (Sigma Chemical, St. Louis, MO, USA). Other reagents were of the highest quality available and obtained from commercial sources. Healthy Spargue Dawley (SD) rats were procured from National Institute of Nutrition, Hyderabad, India. The animal's body weights were in the range of 180 + 10 g and were of 6 weeks old. The experiments were carried out as per the ethical guidelines of ethical committee (CPCSEA). The rats were maintained in plastic cages at hygienic conditions and maintained at room temperature at 25-27°C with 12 hrs light/dark cycle for one week prior to starting the experiments to acclimatize to the laboratory conditions. They received water ad libitum and standard rat diet procured from National Institute of Nutrition, Hyderabad, India. The animals were randomized into 4 groups of 5 animals each. Group-I was provided with normal diet and water served as control. Group-II received a dosage of 100 mg / kg b.w. of aluminium chloride and 10 mg/kg b.w of sodium fluoride. Group III received a dosage of 100 mg / kg b.w. of aluminium chloride + 10 mg/kg b.w of sodium fluoride and 30 mg/kg b.w of resveratrol. Group IV received resveratrol alone with a dosage of 30 mg/kg b.w. All the doses were administered orally between 08:00 – 09:00 hours daily for 8 weeks. For the histological analysis, the animals were sacrificed by decapitation. The brains were removed immediately for the study.

### **Histopathological studies of brain**

The Histopathological studies were carried out according to the method of Luna (1968).

#### **H&E Stain**

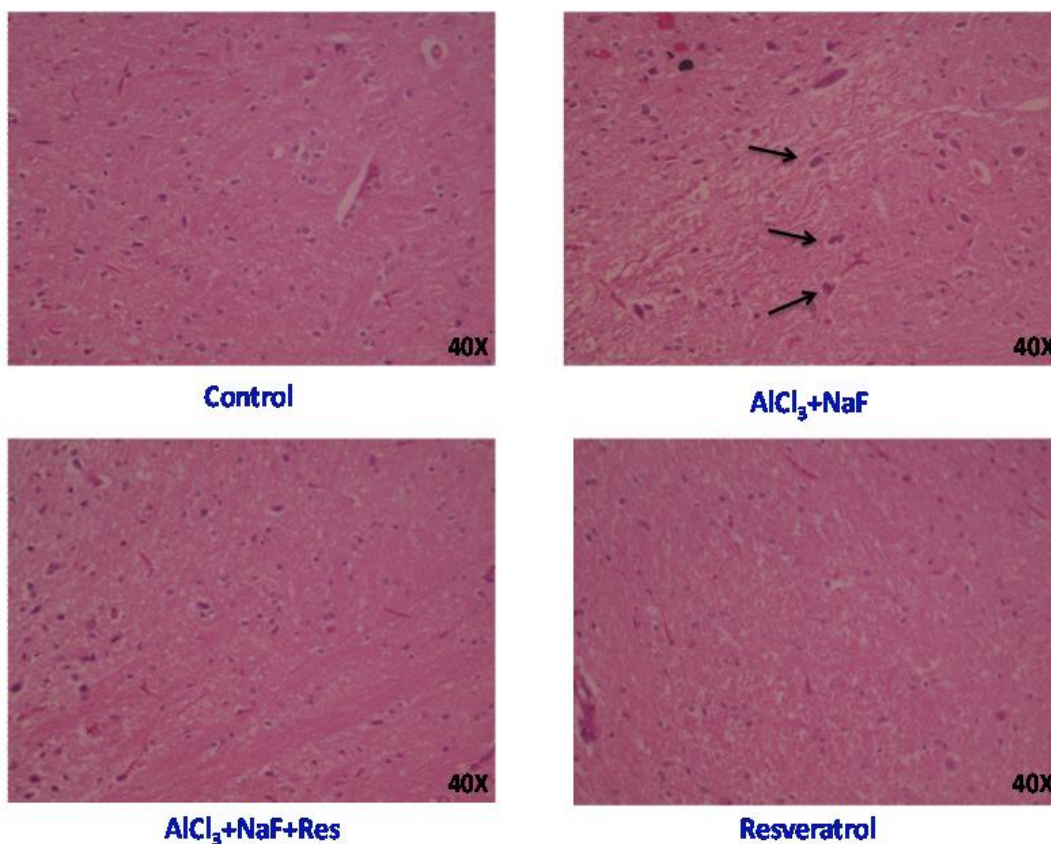
The cerebral cortex of brain tissue was fixed in 10% formaldehyde for 1 to 2 days. Hydrated the tissue serially in 100%, 75%, 50%, 30% alcohol gradients, and distilled water for 10-15 minutes for every change, followed by dehydrated the tissue with 30%, 50%, 70%, 90% and 100% alcohol for 20min for every change and cleared the tissue with two changes of xylene for 10 mins, then kept the tissue in wax at 55°C (minimum two changes required). Embedded the tissue in melted wax (60°C) with using the L blocks for staining. Just before the staining, the tissue was cut into the 5 ( $\mu$ ) sections (Rotary microtome, model No: 45, LipsheW MFG Co Detroit 10 Michigan L-057) with rotary microtome. Transferred the obtained ribbon consist tissue sections onto the 0.5% gelatin coated slides without wrinkles. Kept the slides overnight in dust free chamber. Next day deparaffinized with xyeline I, xylene II for 30 minutes, then hydrated the tissue with 100%, 90%, 70%, 50%, 30% and d.w for 10 minutes every change. Allowed the slides into Harris Haemotoxylin stain solution for 5-15 minutes, and then kept the sections under running tap water for 10 minutes. Dehydrated the sections with 30%, 50%, 70%, 90% alcohol for 10 minutes. Transferred the slides into 1% eosin (alcohol soluble) for 30 seconds, then the slides kept in 100% alcohol, and cleared with Xylene I, Xylene II for 10 minutes, allowed air dry and mounted the sections with DPX without air bubbles.

#### **Congo red stain**

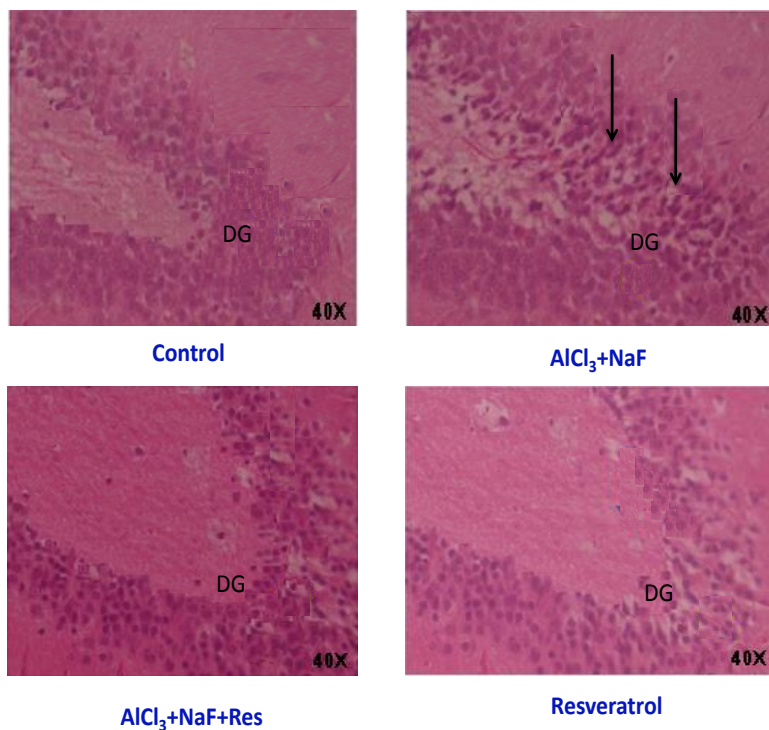
The cerebral cortex of brain tissue was fixed in 10% formaldehyde for 1 to 2 days. Hydrated the tissue serially in 100%, 75%, 50%, 30% alcohol gradients, and distilled water for 10-15 minutes for every change, followed by dehydrated the tissue with 30%, 50%, 70%, 90% and 100% alcohol for 20min for every change and cleared the tissue with two changes of xylene for 10 mins, then kept the tissue in wax at 55°C (minimum two changes required). Embedded the tissue in melted wax (60°C) with using the L blocks for staining. 5 ( $\mu$ ) sections were prepared by the rotary microtome. (Rotary microtome, model No: 45, LipsheW MFG Co Detroit 10 Michigan L-057). Transferred the obtained ribbon consist tissue sections onto the 0.5% gelatin coated slides without wrinkles. Kept the slides overnight in dust free chamber. Next day deparaffinized with xyeline I, xylene II for 30 minutes, then hydrated the tissue with 100%, 90%, 70%, 50%, 30% and d.w for 10 minutes every change. Then rinsed in Congo red solution for 1 hour. After 1 hour, rinsed off excess stain in water, two or three changes and differentiated in alkaline alcohol solution for 3-5 seconds and agitated constantly until the background appears clear. When the background appears clear, washed in running water for 5 minutes. Then Counterstained in Mayer's haematoxylin solution for 5 minutes and washed in running water for 15 minutes. After washing, dehydrated in 95% alcohol, absolute alcohol, and cleared in xylene, two changes each and mounted with permount.

**RESULTS AND DISCUSSION**

The neuronal damage and aggregation was observed in  $\text{AlCl}_3$  + NaF treated group when compared to the control group whereas less neuronal damage and aggregation was observed when Resveratrol administered along with  $\text{AlCl}_3$ + NaF treatment. No morphological variation was observed in Resveratrol alone treated group as compared to the control group.

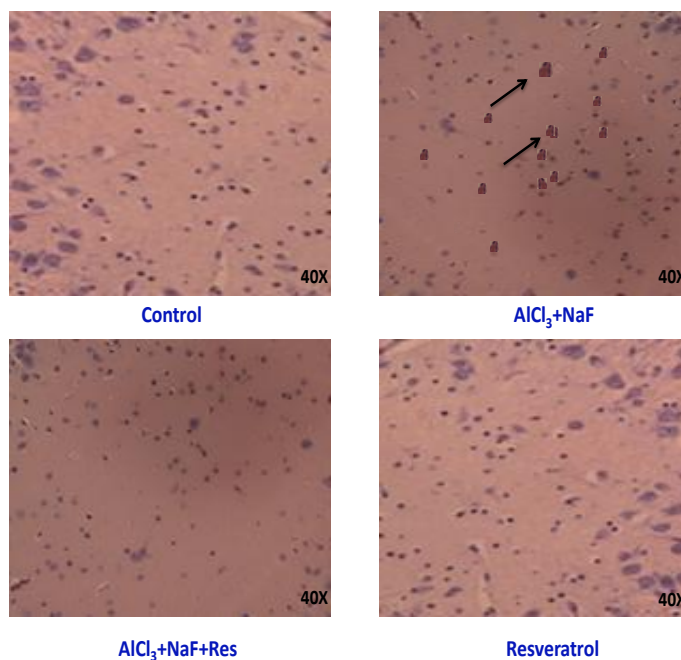


**Fig-1: Brain Histopathological studies in cerebral cortex by H&E stain in control,  $\text{AlCl}_3$ + NaF,  $\text{AlCl}_3$ + NaF + Resveratrol, Resveratrol alone treated groups. (Magnification 40X).**



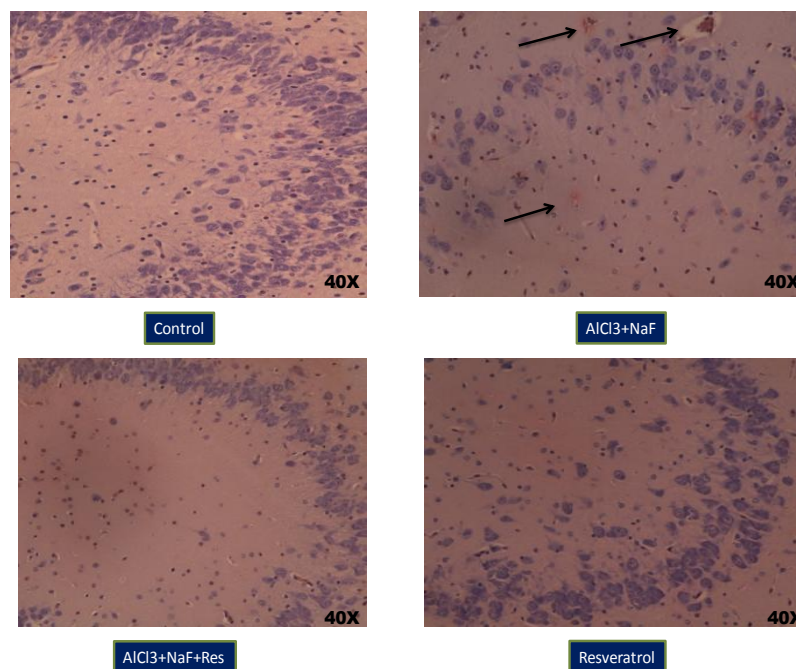
**Fig-2: Brain Histopathological studies in dentate gyrus region of hippocampus by H&E stain in control, AlCl<sub>3</sub>+ NaF, AlCl<sub>3</sub>+ NaF + Resveratrol, Resveratrol alone treated groups. (Magnification 40X).**

The neuronal damage and aggregation was observed in AlCl<sub>3</sub> + NaF treated group when compared to the control group where as less neuronal damage and aggregation was observed when Resveratrol administered along with AlCl<sub>3</sub>+ NaF treatment. No morphological variation was observed in Resveratrol alone treated group as compared to the control group.



**Fig-3: Brain Histopathological studies in cerebral cortex by Congo red stain in control, AlCl<sub>3</sub>+ NaF, AlCl<sub>3</sub>+ NaF + Resveratrol, Resveratrol alone treated groups. (Magnification 40X).**

The amyloid protein plaques were formed in the  $\text{AlCl}_3$ +NaF treated group as compared to the control group. The amyloid plaques were not observed in the Resveratrol along with  $\text{AlCl}_3$ +NaF treated group as compared to the  $\text{AlCl}_3$ +NaF treated group.



**Fig-4: Brain Histopathological studies in dentate gyrus region of hippocampus by Congo red stain in control,  $\text{AlCl}_3$ + NaF,  $\text{AlCl}_3$ + NaF + Resveratrol, Resveratrol alone treated groups. (Magnification 40X).**

The amyloid protein plaques were formed in the  $\text{AlCl}_3$ +NaF treated group as compared to the control group. The amyloid plaques were not observed in the Resveratrol along with  $\text{AlCl}_3$ +NaF treated group as compared to the  $\text{AlCl}_3$ +NaF treated group. Aluminum is a potent neurotoxic element involved in several neurodegenerative disorders characterized with dementia. Sources of Al in medications, water and processed foods have been reported advocating cautious avoidance of Al, particularly for patients with Alzheimer's disease (Lione, 1985; Walton, 2012).

Fluoride exposure increased the production of reactive oxygen species (García et al., 2009, Izquierdo et al., 2008). Oxidative stress is a recognized mode of action of fluoride exposure that has been observed in *in vitro* in several types of cells and also in *in vivo* in soft tissues indicating oxidative damage is the major mode of fluoride action (Ling et al., 2013). The dietary supplementation with the phytoalexin polyphenol resveratrol replenished the performance of aged mice in the acquisition of a Y-maze task and increased the exploration of the center area of an open-field test. The improvement in cognitive performance as observed in the Y-maze was paralleled by an increased microvascular density in the hippocampus and decreased number of vacuolar abnormalities in both hippocampal and cortical microvascular endothelial cells (Charlotte et al., 2009). Brain histological observations in toxic conditions includes oedema accompanied by disrupted and degenerated neurons in the area, vacuolization around the neuron/perineuronal space/spongiosis, disruption of nucleus and congestion in the blood vessels, dense cytosolic staining (Jyoti and Sharma, 2006), a damage in the hippocampus and cortex, including neurofibrillary degeneration, due to the accumulation of Al in these regions (Rebai and Djebli, 2008). In this investigation neuronal aggregation was observed in the cortex of aluminium chloride along with sodium fluoride treated group due to the neuronal destruction which suggests aluminium and fluoride exerted their toxic effects through oxidative stress as a result of excitotoxicity as compared to the control group.

The present results also corroborates that the compounds both aluminium and fluoride form a complex and accumulated in the brain and elevated free radicals and peroxidation levels which caused oxidative stress as well as prolonged neurotoxicity which led to neuronal damage (Blaylock, 2004, 2012; Hao et al., 2013).

The aluminium and fluoride toxic effects on cerebral cortex were reversed in the group received resveratrol against aluminium chloride along with sodium fluoride. The obtained results are supported by the earlier studies showing administration of resveratrol to rats was associated with improved histological, motor, and cognitive functions, as measured by postural reflex and forelimb placement, corner test, foot-fault test and water maze performance (Kwon et al., 2011; Singleton et al., 2010). On the other hand, the Resveratrol alone administered animal group was not shown any manifestation as compared to the control group, which suggests that Resveratrol can not affect the healthy individuals and has ameliorative effect. In the present study Al and F toxicity was investigated in the dentate gyrus region of the hippocampus in rats. The dentate gyrus was chosen for a number of reasons: aluminium affects the hippocampus more severely than any other area of the central nervous system (Urano et al., 1997) and this brain region was known to be particularly susceptible in Alzheimer's disease, a neurodegenerative disorder (Deloncle and Guillard, 1990) and have an important role in memory and learning functions. The dentate gyrus region of the hippocampus provides an attractive target zone for  $AlCl_3 + NaF$  effect which showed morphological alterations in the sub granular layer with modulation of the dentate gyrus appearance. In fact, treated rats showed a normal sub granular layer but abnormal appearance of dentate gyrus curvature due to migration of neuroblasts to the cortex surface compared to the control. This can be explained by an increase in the neuroblast turnover or in the cell death by necrosis. In this study, the dentate gyrus curvature was opened and that the opposite zones extended to the cortex surface or the Cornu Ammonis as compared to the control group. The results corroborates Hichem et al (2014) study that the long-term oral  $AlCl_3$  intake through drinking water results in an accumulation of this metal in plasma and brain causing detrimental effects on body and brain weight and dentate gyrus structure. The observed pathological alterations were minimized in resveratrol administered against aluminium and fluoride group. The results were supported by Catrinel and Plamondon (2015) study that examined the effects of resveratrol pretreatment on microglia and astrocyte activation and characterized GLT1 expression in the dentate gyrus (DG), CA1 and CA3 layers of the hippocampus. On the other hand, resveratrol alone administered group was not shown any variation as compared to the control group. This indicates the ameliorative properties of resveratrol. Aluminium can also induce neurotoxicity via impairing neuronal exchange of calcium ions and increase  $Ca^{2+}$  level in brain (Goma and Mahrous 2013). The increased  $Ca^{2+}$  causes mitochondrial overload, excessive production of  $A\beta$ , and tau hyperphosphorylation which further generate caspases and cytochrome c and increase ROS production leading to cell death and neurodegeneration (Stutzmann 2007).

Amyloid- $\beta$ , the primary component of amyloid plaques, is generated by the sequential cleavage of the amyloid precursor protein (APP) via the APP cleaving enzyme ( $\alpha$ -secretase, or  $\beta$ -secretase) and  $\gamma$ -secretase. The excessive production of  $A\beta$ , and tau protein hyperphosphorylation leads to the formation of amyloid (senile) plaques and neurofibrillary tangles, hall marks of neurodegenerative disorders such as Alzheimer's disease (Cai et al., 2011). Alzheimer's disease (AD) is a multifactorial disorder characterized by an insidious onset and progressive decline of cognitive functions, representing up to 70% of all cases of dementia among the elderly (Reitz et al. 2011). Key hallmarks of this type of dementia are aberrant processing of amyloid precursor protein (APP) leading to deposition of  $\beta$ -amyloid peptides (Ab) in form of senile plaques, as well as hyperphosphorylation of tau protein, responsible for the formation of neurofibrillary tangles (Maccioni et al. 2001). In the present investigation the amyloid (senile) plaques were observed in the cerebral cortex and dentate gyrus region of the hippocampus in Al and F intoxicated group when compared to the control group were supported with earlier studies. Furthermore, the abnormalities were not noted in the presence of resveratrol when administered against Al and F intoxicated rats. This observation is in agreement with the earlier findings of Karuppagounder et al (2009).

In conclusion, the in vivo study reports that the resveratrol significantly ameliorated structural and degenerative changes in neurons of cortex and dentate gyrus region of hippocampus effects of aluminium and fluoride in rat brain. Thus, this report suggests that the resveratrol is robust in preventing histopathological alterations in rat brain.

## ACKNOWLEDGEMENT

The authors are acknowledged the UGC-DSA-I and BSR for providing financial support.

## REFERENCES

- Ahmed E. Abdel Moneim. (2012). Evaluating the Potential Role of Pomegranate Peel in Aluminum-Induced Oxidative Stress and Histopathological Alterations in Brain of Female Rats. *Biol Trace Elem Res.*:150:328–336.
- Ansari MA, Scheff SW. (2010). Oxidative stress in the progression of Alzheimer disease in the frontal cortex. *J Neuropathol Exp Neurol.*:69:155–67.
- Blaylock RL. (2004). Excitotoxicity: a possible central mechanism in fluoride neurotoxicity. *Fluoride.*:37:201-314.
- Cai Z, Zhao B, Ratka A. (2011). Oxidative stress and - amyloid protein in Alzheimer's disease. *Neuromol Med.*: 13, 223-250.
- Catrinel Girbovan, Hélène Plamondon. (2015). Resveratrol down regulates type1 glutamate transporter expression and microglia activation in the hippocampus following cerebral ischemia reperfusion in rats. *Brain Research.*: 1608 (22), 203–214.
- Celeste Di Paolob, Ingrid Reverte, Maria Teresa Colomina, José L. Domingo b, Mercedes Gómez. (2014). Chronic exposure to aluminum and melatonin through the diet: Neurobehavioral effects in a transgenic mouse model of Alzheimer disease. *Food and Chemical Toxicology.*: 69 320–329.
- Charlotte A. Oomen\*, Eszter Farkas, Viktor Roman, Eline M. van der Beek, Paul G. M. Luiten and Peter Meerlo. (2009). Resveratrol preserves cerebrovascular density and cognitive function in aging mice” *Frontiers in aging neuroscience.*: Vol 1, Article 4, 1-9.
- Deloncle, R., Guillard, O. (1990). Mechanism of Alzheimer's diseases: arguments for a neurotransmitter aluminum complex implication. *Neurochem. Res.*: 15, 1239–1245.
- E. A. García-Montalvo, H. Reyes-Pérez, and L. M. Del Razo. (2009). Fluoride exposure impairs glucose tolerance via decreased insulin expression and oxidative stress. *Toxicology.*: vol. 263, no. 2-3, pp. 75–83.
- Goma AA, Mahrous UE (2013). Ethological problems and learning disability due to aluminum toxicity in rats.: *Ani Vet Sci* 1:12–17.
- Hao Lu, Jianyang Hu, Jing Li, Wei Pang, Yandan Hu, Hongpeng Yang, Wenjie Li, Chengyu Huang, Mingman Zhang, and Yugang Jiang, M.D. (2013). Optimal dose of zinc supplementation for preventing aluminum induced neurotoxicity in rats. *Neural Regen Res.*: 8(29): 2754–2762.
- Humpel C (2011). Chronic mild cerebrovascular dysfunction as a cause for Alzheimer's disease? *Exp Gerontol* 46:225–232.
- Jyoti, A., Sharma, D. (2006). Neuroprotective role of Bacopa monniera extract against aluminium-induced oxidative stress in the hippocampus of rat brain. *Neurotoxicology.* 27, 451–457.
- Kaizer RR, Corre`a MC, Spanevello RM et al. (2005). Acetylcholinesterase activation and enhanced lipid peroxidation after long term exposure to low levels of aluminum on different mouse brain regions. *J Inorg Biochem.*: 99:1865–1870.
- Kwon, K.J., Kim, J.N., Kim, M.K., Lee, J., Ignarro, L.J., Kim, H.J., Shin, C.Y., Han, S.H. (2011). Melatonin synergistically increases resveratrol-induced heme oxygenase- 1 expression through the inhibition of ubiquitin-dependent proteasome pathway: a possible role in neuroprotection. *J. Pineal Res.* 50, 110-123.
- Lakshmi BV, Sudhakar M, Anisha M. (2014). Neuroprotective role of hydro alcoholic extract of Vitis vinifera against aluminium-induced oxidative stress in rat brain. *Neurotoxicology.*: 41:73–79.
- Ling Yan, Shengnan Liu, Chen Wang, Fei Wang, Yingli Song, Nan Yan, Shuhua Xi, Ziyou Liu, and Guifan Sun. (2013). JNK and NADPH Oxidase Involved in Fluoride-Induced Oxidative Stress in BV-2 Microglia Cells, Mediators of Inflammation.: Volume 2013, Article ID 895975, 1-10.



- Maccioni RB, Munoz JP, Barbeito L. (2001). The molecular bases of Alzheimer's disease and other neurodegenerative diseases. *Arch Med Res.*: 32:367–381.
- Poonam Meena, Apra Manral, Vikas Saini (2015). Protective Effects of a Piperazine Derivative [N-{4-[4-(2-methoxyphenyl)-piperazin-1-yl]-phenyl} Carbamic Acid Ethyl Ester] Against Aluminium-Induced Neurotoxicity: Insights From In Silico and In Vivo Studies. *Neurotox Res.*: 27:314–327.
- Prakash A, Shur B, Kumar A (2013). Naringin protects memory impairment and mitochondrial oxidative damage against aluminium-induced neurotoxicity in rats. *Int J Neurosci.*: 123:636–645.
- Querfurth HW, LaFerla FM (2010). Alzheimer's Disease. *N Engl J Med.*: 362:329–344.
- Rebai, O., Djebli, N.E. (2008). Chronic exposure to aluminum chloride in mice: exploratory behaviors and spatial learning. *Adv. Biol. Res.*: 2, 26–33.
- Reitz C, Brayne C, Mayeux R. (2011). Epidemiology of Alzheimer disease. *Nat Rev Neurol.*: 7:137–152
- S.S. Karuppagounder, J.T. Pinto, H. Xu, H.L. Chen, M.F. Beal, G.E. Gibson, (2009). Dietary supplementation with resveratrol reduces plaque pathology in a transgenic model of Alzheimer's disease. *Neurochem. Int.*: 54, 111–118.
- Sharma Chhavi, Pooja Suhalka, Piyu Sukhwal, Neha Jaiswal, Maheep Bhatnagar. (2014). Curcumin attenuates neurotoxicity induced by fluoride: An in vivo evidence, *Pharmacognosy Magazine.*: 10 (37): 61-65.
- Singleton, R.H., Yan, H.Q., Fellows-Mayle, W., Dixon, C.E. (2010). Resveratrol attenuates behavioral impairments and reduces cortical and hippocampal loss in a rat controlled cortical impact model of traumatic brain injury. *J. Neurotrauma.*: 27, 1091-1099.
- Song Y, Xue Y, Liu X, Wang P, Liu L. (2008). Effects of acute exposure to aluminum on blood–brain barrier and the protection of zinc. *Neurosci Lett.*: 445:42–46.
- Stevanovic ID, Jovanovic MD, Colic M, Jelenkovic A, Mihajlovic R, Stojanovic I, Ninkovic M (2010). The effect of amino guanidine, an inducible nitric oxide synthase inhibitor, on AlCl<sub>3</sub> toxicity in the rat hippocampus. *Arch Biol Sci.*: 62:981–991.
- Stutzmann GE. (2007). The pathogenesis of Alzheimer's disease—is it a life long “calciumopathy”. *Neuroscientist.*: 13(5) 46–559.
- Urano, S., Asai, Y., Makabe, S., Matsuo, M. (1997). “Oxidative injury of synapse and alteration of antioxidative defence systems in rats and its prevention by Vitamin E. *Eur. J. Biochem.*”. 245, 64–70.
- Van der Voet GB, Schijns O, de Wolff FA. (1999). Fluoride enhances the effect of aluminium chloride on interconnections between aggregates of hippocampal neurons. *Arch Physiol Biochem.*: 107:15-21.
- Varner JA, Jensen KF, Horvath W, Isaacson RL. (1998). Chronic administration of aluminum-fluoride or sodium-fluoride to rats in drinking water: alterations in neuronal and cerebrovascular integrity. *Brain Res.*: 784:284-98.
- Walton, J.R., (2012). Evidence that total dietary ingestion is a major risk factor for Alzheimer's disease. *Curr. Inorg. Chem.* 2, 19–39.
- Yokel RA (2006). Blood-brain barrier efflux of aluminium, manganese, iron and other metals suspected to contribute to metal-induced neurodegeneration. *J Alzheimers Dis.* 10:223–253 Review.

ISSN : 0976-4550

# INTERNATIONAL JOURNAL OF APPLIED BIOLOGY AND PHARMACEUTICAL TECHNOLOGY



Email : [ijabpt@gmail.com](mailto:ijabpt@gmail.com)

Website: [www.ijabpt.com](http://www.ijabpt.com)